

A venomous snakebite case in Australia supports the efficacy of Sutherland's original 1979 pressure immobilisation first aid.

Brian Bush*

*Manager, Snakes Harmful & Harmless, 9 Birch Place, Stoneville, Western Australia 6081
Address all correspondence to – bush@iinet.net.au

Abstract

The venoms of Australian snakes rarely cause necrosis, but on three occasions the author has experienced bite site tissue injury since employing pressure immobilisation first aid where a bandage is applied directly over bite site as per Sutherland *et al.* (1979): once by Tiger Snake (*Notechis scutatus*) and twice by Common Mulga Snake (*Pseudechis australis*). This may demonstrate the efficacy of that first aid treatment in sequestering the concentrated venom to the bite site. It is suggested that the local tissue damage is a result of the quantity of venom injected and not related to the time the bandage is in place. Included also is a firsthand account of a bite from *P. australis* that occurred in a remote location without medical assistance and a photographic record of the envenomed finger showing progressive destruction of tissue and partial natural resolution.

Introduction

Australia has a large number of venomous snake species, with about 134 of these being front-fanged marine and terrestrial Austropapuan elapids. About 3,000 bites are reported annually with as many as 500 of these requiring hospitalisation and an average of two being fatal (Johnston *et al.* 2017, Welton *et al.* 2017, White 1998).

First aid treatment for snakebite to limbs in Australia since late 1979, has involved the use of a pressure bandage firmly applied to the bite site and extended as high as possible, before extending the bandage back down the limb to the extremity, then immobilising the limb with a splint or similar and known as pressure immobilisation (PI) first aid (Figure 1). Developed by Sutherland *et al.* (1979), this treatment has since been variously modified with minor changes that can only contribute to the confusion a layperson may experience when called upon to perform emergency snakebite first aid. In 1997 the Western

Australian Health Department suggested the bandage be bound over the bite and then extended to the extremity before proceeding to bind up the limb. In 2001 Sutherland *et al.*, when using a single bandage to achieve *both pressure to the bite site and immobilisation of the limb*, suggested commencing bandaging at the extremity, extending it up the limb over the bite and as high as possible. In 2005, the Australian Resuscitation Council reverted to the original 1979 first aid and stated that a simple pressure bandage over bitten area leads to at least partial occlusion of capillaries and lymphatics. It also provides the alternative, when the bite is not on a limb, to apply firm direct pressure on bite site. In 2014, St John Ambulance combined the 2001 technique with the original 1997 PI first aid, suggesting the use of two bandages with the first being applied directly over the bite and then a second, commencing at the fingers or toes, covering the whole limb. In 2017, the Department of Pharmacology and Therapeutics, The University of Melbourne made recommendations (discussed below),

that, whilst accurate, risk complicating emergency snakebite first aid. Their recommendations appear impossible to achieve in an emergency situation unless the victim or bystander has on their person a cloth pad and a gauge capable of reading bandage pressure; and there is little alternative improvisation first aid provided.

Rarely is local tissue damage seen as a major result of Australian snakebite. It is fortunate that this is the case because in many other countries some snakes possess powerful tissue-destroying venoms that are severely debilitating to victims and in many cases have caused such significant damage to a limb that required its amputation. Although bite site tissue destruction is not often observed in Australia, it has been reported by White (1987) after bites from Tiger Snake (*N. scutatus*), Taipan (*Oxyuranus scutellatus*) and Common Mulga Snake (*P. australis*). Razavi *et al.* (2014) when looking specifically at *P. australis* bites, found about ten percent (2 of 21) of envenomed subjects developed local tissue injury around the bite site that required further treatment. Snake exhibitor, Neville Burns required the surgical removal of a finger after a bite from a Red-bellied Black Snake (*P. porphyriacus*) (N. Burns pers. comm.); and during this study, the author had it reported to him that in March 2017 a victim's toe required amputation after a bite near Lismore, New South Wales from a Rough-scaled Snake (*Tropidechis carinatus*) (T. Tasoulis pers. comm.). In all of these cases PI first aid was applied.

It has been suggested that local tissue damage after snakebite may be a result of leaving the pressure bandage in place for a considerable period (Harvey *et al.* 1982, Sutherland *et al.* 1981a), however, if this is the case, there is no available solution because the time the bandage is in place is determined by several variable, but uncontrollable factors, especially in Australia because of the vast distances impacting on the time it takes to recover a victim when isolated in the bush; and particularly so when the general recommendation is that the bandage be left in place until medical treatment is sourced and then the doctor is the one deciding when to remove it. Although the first aid treatment should not put the patient at risk, the loss of a

digit, or local scarring is a small price to pay by the victim, if their death is the alternative as a consequence of premature removal of the bandage.

In the case history reported here, the bandage was removed from the bitten area (finger and hand) seventy-five minutes after envenomation, although the degree of necrosis in this record is the most severe of the three bites where the author experienced local tissue damage. In all of these, the snakes involved hung on and had to be grasped by the head to be removed, suggesting a maximum amount of venom injected.

Author's background –

I describe myself as a field herpetologist that for over sixty years has been involved with reptiles. This was initially as a hobby in the early days, but since 1976 I have collected reptile specimens for the Western Australian Museum (WAM) and other institutions; and since 1987 I have run a reptile education and venomous snake consultancy business, which primarily involves providing occupational health and safety training to manage snakes in remote workplaces, especially for the resource industry in Western Australia (WA).

As a part of this job, I spend about two-thirds of each year alone driving between mine sites and camping in the bush to avoid the soft life of the company camps, but more importantly to allow me to find, examine and photograph wild reptiles under various licences issued by the WA wildlife authority, currently the Department of Biodiversity, Conservation and Attractions.

This regular and consistent handling of snakes has exposed me to several serious bites, especially by the large medically significant species, with a total of seven envenomations where I had medical intervention at various metropolitan and regional hospitals (Table 1). There were also numerous other bites where the circumstances at the time precluded me from seeking medical assistance and I just had to “weather the storm”, relying only on the tourniquet treatment in the early days and on PI first aid since the early 1980's to pull me through.

Because of my history, snakebite holds no mystery to me, but I appreciate the psychological trauma the average citizen may experience after a bite, especially because of their possible exposure to the exaggerated negative misinformation often presented by the media and others regarding Australian snake venom toxicities obtained initially during laboratory studies on mice by Broad *et al.* (1979). I believe this has resulted in the experiences of many snakebite victims reported by the media being overly emotive accounts reflecting the heightened trauma each survivor was exposed to at the time.

Although mulga snakebite has the potential to cause death, this is exceedingly rare, with the last confirmation I can find attributed to this species being in 1969 when Tiger Snake antivenom was used instead of Black Snake (Jelinek *et al.* 2004, Sutherland *et al.* 2001). Snake exhibitor, Fred Duffy's death in 1977 is listed as the result of mulga snake bite by Mirtschin (2006), but a question mark has been included in this record regarding the authenticity of the identification of the species involved.

The primary concern with this most recent bite at the time was my small body size (70kg) and age of nearly seventy years. Both these factors were against me and could possibly increase the negative effect of the venom. On the positive side, I considered my previous history and exposure to mulga snake venom could be beneficial. This included medical management and antivenom in 1997 and in 2000, a case in which no medical intervention was involved after a bite from a Spotted Mulga Snake (*P. butleri*), reported by Bush (2013). I considered they may have combined to provide me with a higher specific antibody titre than most, however Isbister *et al.* (2010) found that human antivenom antibodies in a previously bitten snake handler did not provide much protection from snake envenomation in his case.

Common Mulga Snake (*P. australis*) –

The Common Mulga Snake is also known as King Brown Snake (Figure 2) and is a large widely distributed member of the Black Snake group. As is typical of most Australian snakes, it is quick to retreat if given the opportunity, but when cornered or handled, some

individuals will bite savagely, hanging on and chewing. Patients receiving its bite may require Black Snake antivenom during treatment and this is probably the case also after bites from closely related Spotted Mulga Snake (*P. butleri*) and Weigel's Mulga Snake (*P. weigeli*). However, this would be specifically identified when diagnosis is made using the venom detection kit (VDK). Tiger Snake antivenom is considered an effective neutralising agent for several eastern Australian members of this group, namely Collett's Snake (*P. colletti*), Blue-bellied Black Snake (*P. guttatus*) and Red-bellied Black Snake (*P. porphyriacus*) (White 1995).

The Common Mulga Snake can yield exceedingly large volumes of venom; with previous 'milkings' I have undertaken commonly exceeding 350mg dried weight. The maximum yield produced by a large individual was 1500mg recently reported by the Australian Reptile Park in New South Wales (Australian Reptile Park 2016).

Its venom consists primarily of myotoxins, which damage muscle tissue, a powerful anticoagulant, but no procoagulants. The venom may also include weak neurotoxins. The clinical effects expected in a patient are local pain, extensive swelling, blood weeping from the bite site, local necrosis (this study), muscle protein and blood in urine, muscle weakness; and in the long term, some reduction in muscle mass. Less likely effects are paralysis and kidney damage (Harris 1983, Johnston *et al.* 2013, Marshall & Herrmann 1983, Sutherland *et al.* 1981b, White 1995).

It is generally known that herpetologists working with snakes can become increasingly sensitised to some species and their venoms (Isbister *et al.* 2013). This is the case with the author and especially so with two members of the Black Snake Group (*P. australis* and *P. porphyriacus*), along with Jan's Banded Snake (*Simoselaps bertholdi*), Rosen's Snake (*Suta fasciata*) and Little Spotted Snake (*S. punctata*). Exposure to the venoms of these snakes triggers mild to severe anaphylaxis, which can be rapid in its onset and quite debilitating.

This bite and symptoms experienced –

On 12 March 2017 at 07.15am 250 km southeast of Port Hedland, WA while photographing a female Common Mulga Snake of 160cm in length, it flicked up and bit my left index finger. As is typical of the species, it hung on chewing and I had to grasp it by the back of the head, holding it on each side between my right index finger and thumb, and then push forward to disengage the recurved fangs from my flesh. This action in itself is problematic because the positioning of my grip was over the venom glands where any pressure has the potential to increase the quantity of venom injected.

I immediately applied PI first aid to the finger and extended it up the limb as high as possible, then folding my arm across my body and firmly positioning it arm-sling fashion against my chest, I grabbed my notebook and sat down to document the event.

My circumstances at the time were such that I could not call for assistance. I was parked in the bush a long way from anywhere. The daytime temperatures in March are high fluctuating around 36°C. My vehicle was full of snakes and any emergency recovery would have involved my evacuation by Royal Flying Doctor Service, but my vehicle would have been left there unattended. I had no choice but to be pragmatic and hope I would survive without medical intervention. If I did succumb to the venom, the snakes in my vehicle would have surely died too.

The first symptoms I was aware of within minutes, apart from local pain and discomfort to the bitten finger and back of the hand, was what I have always believed to be mild anaphylaxis involving itchy skin, particularly the scalp, armpits, underside of arms and the inside of my legs, along with a blotchy rash that was most obvious in these same areas. My face also became blotchy and slightly swollen, while my mouth was very dry and my nose was running. I remember being surprised that the anaphylaxis resolved itself quite quickly and although waves of light-headedness and feeling faint rolled over me continually for the first hour or so, it did not progress to the severely discomforting stage I had previously experienced after bites from Rosen's Snake, Little Spotted Snake and Jan's

Banded Snake. In retrospect, I wonder if the reduction in anaphylactic symptoms was more an illusion in my mind brought on by the pronounced deterioration in my health as a result of the envenomation?

Nevertheless, I felt exceedingly sick!

The pain in my finger and hand was increasing and I could feel them swelling under the pressure bandage. I could also see this in my extremely swollen fingers. My ring finger was a strange dumb-bell shape due to the restriction of the swelling caused by my wedding ring. Thinking this complication may add to my trauma, I tried to cut the ring off with a pair of scissors I kept in the back of my vehicle. These, along with a pair of long-nosed pliers were within arm's reach of where I was sitting. I had to revert to the scissors, which broke during the attempt, because the pliers that I initially tried were too thick to slide between the ring and my swollen flesh.

I was cranky with myself, why did I not think of taking the ring off immediately after applying the pressure bandage?

It is now thirty minutes post bite and I felt progressively more ill, but not in the stomach, it was more a sensation in the head, along with a feeling of weakness as my strength drained away. At this point, the dryness of my mouth was unpleasant, so I now needed a drink, both because of my dry mouth and because I was actually thirsty. It was when standing to do this that I realised just how weak I was. I nearly fell to the ground and to stop myself, I basically flopped forward onto the gear in the back of my vehicle, but it did put me in reach of the water bottle. My initial intent was to stand, walk to the driver's door, climb in and reach over to the back seat to grab some cold water from the car fridge, but I was incapable of doing this, so had to contend with marginally warmer water than was hoped for. I was looking quite sick approximately half-hour after taking the bite as was obvious in a selfie I took at that time.

At 08.30, one hour and fifteen minutes in, my hand felt quite cold, so I loosened the pressure bandage over my finger and hand to the wrist, but leaving it firmly in place up my arm to the armpit. Drinking the water refreshed

me a little and over the next couple of minutes the circulation returned to my hand as it was tingling and warm again. At this point my writing in the notebook starts deteriorating and twenty minutes later (08.50), my notes are becoming incoherent (Figure 3). I believe some of the annotation is,

“Another wave of ana – feint.” (sic)

Then indecipherable scribbling followed by,

“Past ana stage not.”

Then indecipherable again followed by the time of 08.50.

This entry at 08.50 is followed by indecipherable rubbish, however, some time after, I recall crawling to my swag, which fortunately was on the shaded northwestern side of the vehicle, removing my pants because of previous experiences of uncontrollable faecal leakage after bites from *Notechis* and *Pseudechis*, and then assumedly passed out, or maybe I just fell asleep, not awakening until 14.00 about five hours later. My writing improved considerably from this point forward, although I was very weak, all my joints were sore and I could not initially stand up unsupported, so worked my way around to my chair by leaning against the vehicle. Seven hours had lapsed since the bite and, although I lacked strength, I felt much less ill than I had earlier. I removed the pressure bandage from the remainder of my arm and photographed my bruised finger (Figure 4A). My mouth was dry and I expected to be thirsty, but I did not drink anything again that day. I just stretched my legs out, laid back and relaxed into that euphoric state between sleep and vague consciousness until the sky was lightening to the east as the new day dawned.

It is Monday 13 March, about twenty-four hours post bite and I am feeling much better, I boiled the billy and made myself a coffee. My fingers, hand and arm were extremely swollen and sore, the snakebite wound on my finger was weeping blood and I was still weak, but could move around now unsupported. I was elated that my animals and I had survived the ordeal to this stage and I would be able to continue with my work – my

next job was the following day near Port Hedland, so that afternoon I drove the 280 kilometres to my regular camp near the Petermarer Creek, thirty kilometres east of the site where I will be undertaking the work.

I felt quite weary shortly into the drive, so twice in the next three hours, I had to park up and have a coffee to refresh me.

Early the following morning I wrapped a dressing around my finger, which continued to weep blood and look unsightly (Figure 4B). I am grateful that long-sleeve shirts are a requirement on site as this will hide my swollen arm and partly cover my swollen hand. I took a couple of headache tablets for the pain and managed to perform my job OK. I did experience some extensive bleeding during my work and when those on the course asked how I had injured my hand, I lied by saying that I had accidentally dropped a rock on it. I continued this dishonest response to my students for the next week and felt extremely bad for doing so.

It would not be until six days after the bite that my blood clotting returned to normal and the wound stopped bleeding, although gangrene had turned the finger black distally and along the underside where the venom would have been most concentrated when injected during the bite (Figure 4C). The finger was to deteriorate much more with tissue destruction before partial recovery basally that extended towards the tip (Figure 4D to I). After four months, it has not completely healed and may still require some surgical intervention to tidy it up.

At the same time my body weight, which dropped shortly after the bite to 65kg, has since increased to 67kg, but by the appearance of my muscles and their additional post bite wrinkling, especially on the forearm and bicep of my left arm, I doubt very much that I will return to my pre bite weight. In mulga snake envenomations like this case, Blacksnake antivenom therapy, as recommended by Johnston *et al.* (2013), would neutralise the venom and reduce the long-term muscle destruction I have experienced after multiple untreated bites from this species group.

Discussion

The suggestion by Harvey *et al.* (1982) and Sutherland *et al.* (1981a) that the local destruction of tissue after Australian snakebite may be a result of the pressure bandage being left in place too long cannot be applicable in this case, as it was released from the finger and hand after only one hour and fifteen minutes. This is exceptionally quick compared to my previous experiences where medical intervention was involved. In all of those cases, the bandage was left in place for periods of no less than four hours and generally much longer, with about 30% of this elapsed time exhausted during the initial notification and transportation process. I argue here that the potential for tissue damage is more likely associated with the volume of venom administered and the rapidity at which pressure is applied to the bite site, rather than the duration the bandage is in place. A quick application of the bandage directly over the bite site would compress the tissue trapping much of the venom and reducing its spread from the bite site. However, any delay in applying pressure would see the venom disperse away from the bite site into the tissue reducing the likelihood of tissue damage through dilution by interstitial and lymph fluid. Although the venom may be progressively diluted over time, it would only be in regard to its necrotising ability and the reverse would be the case regarding the degree of systemic envenomation it may cause.

A USA study by Bush *et al.* (2004) found applying PI first aid delays mortality after rattlesnake envenomation in a porcine model, but did not recommend its use because it contributed to an increase in intracompartmental pressure and tissue damage, however, after speaking to doctors in Japan in 2003, I was advised PI first aid was recommended there for treatment of pit viper bite, although in the southern islands, they persist with the traditional treatment of applying a constrictive band or tourniquet immediately above the bite. Photos I viewed at the time comparing limb damage after bites from Habu (*Trimeresurus flavoviridis*) showed a significant degree of tissue damage in those patients where the constrictive band was used, whereas in those cases where PI first aid was

applied, the damage was much more reduced in its spread, but it did penetrate deeper supporting the findings of Bush *et al.* (2004), however the more localised necrosis did reduce the crippling impact many victims otherwise experienced after the traditional treatment.

Figure 5 shows localised necrosis experienced by the author after previous envenomations from *P. australis* (top) on index knuckle of left hand at forty-eight hours post bite and *N. scutatus* (bottom) on outside of right wrist at twenty-four hours post bite. In both cases, pressure was immediately applied to the bite site and in both cases the tissue damage was sufficiently extensive to result in a permanent scar.

Conclusion

The localised tissue damage observed today in envenomed victims of bites from some species of Australian venomous snakes, namely Tiger Snake (*N. scutatus*), Coastal Taipan (*O. scutellatus*), Common Mulga Snake (*P. australis*), Red-bellied Black Snake (*P. porphyriacus*) and Rough-scaled Snake (*T. carinatus*) is considered here to be a result of pressure to the bite site compressing the tissue and trapping nearly all the venom to this small area. The quicker it is done, the greater probability of venom being concentrated at the bite site. Other Australian snakes with similar venoms can be expected to cause local tissue injury also. These are copperheads (*Austrelaps* spp.), broad-headed snakes (*Hoplocephalus* spp.), Lake Cronin Snake (*Paroplocephalus atriceps*), the other two taipans (*O. microlepidotus* and *temporalis*) and the other black snake and mulga snake species (*P. butleri*, *colletti*, *guttatus* and *weigeli*).

The recent update to Australian snakebite first aid by Department of Pharmacology and Therapeutics, The University of Melbourne in 2017 suggesting bandage application commence at extremity of limb irrespective of position of bite (see Introduction: 2nd paragraph), the inclusion of a pad over the bite, which may improve venom sequestration, but is not always feasible, especially if bite is on toe; and stating specific pressure (40 mmHg for arm and 50 mmHg for leg) are all requirements that will be difficult to

achieve in a real-life emergency situation outside the laboratory. We need to limit confusion in the first instance, especially considering that the paramedic's intervention is second aid, with first aid undertaken by the victim or bystanders to provide time to allow for more intensive treatment by ambulance officer or hospital emergency department staff. Improvisation, based on what is immediately available, is often the most important first intervention and for any satisfactory outcome, the *quick* application of adequate first aid is the best. This can consist of immediate pressure firmly applied with the flat of the hand directly over bite site until something more suitable can be sourced as a 'pressure bandage'. Keep in mind; this direct pressure with flat of hand is the only first aid suitable for bites on the face or trunk of body, which fortunately are uncommon, with 90% of *accidental* bites on foot or lower leg and 8% on hand or forearm (Bush and Maryan 2011).

Since its development in 1979, PI first aid has been heavily scrutinised. Just recently, Johnstone *et al.* (2017) in a study of snakebite in Australia concluded that there is a lack of strong evidence that it improves outcomes. However, those Australian snakes with a necrotising component to their venom reported here may actually be causing local damage as a result of the efficacy of PI first aid in sequestering the concentrated venom to the bite site. The long-term consequences of this damage may be scarring or rarely the loss of a finger or toe. Considering the alternative, in all 13 reported deaths from snakebite in WA since 1980, no PI first aid was employed (Bush

2016); so localised tissue damage is a small price to pay for an otherwise good outcome.

Acknowledgements

To the participants in my March 2017 courses, especially those attending Port Haven, Newman, Pundulmurra, Eramurra and Kurra, I would like to apologise for my lack of honesty when I stated that a falling rock caused the damage to my hand.

Robert Browne-Cooper, Simon Ball and Vicky Johnson provided valuable comments and suggestions during the preparation of this paper, while Timothy Jackson assisted significantly in the development of the final draft.

I have got to make special mention of my wife, Judy who has stood by me and in so doing been more traumatized by my snakebites than I. She has had to contend with my going away and then never sure if I shall return, or at least getting calls on several occasions from hospital employees explaining that I've been admitted for snakebite. My daughters, Kylie and Julie have had to carry the uncertainty too, at least for the past forty years. Thanks to you all as I would have never been able to do my job without you.

For their support of my decision to go with nonmedical intervention, I thank my GP, Dr Frank Koti and surgeon, Mr Andrew Crocker.

References

- Australian Reptile Park. 2016. King Brown Snake (*Pseudechis australis*) venom milking record broken!
<https://www.youtube.com/watch?v=IwTZDA7X8iA>
- Australian Resuscitation Council. (2005) ARC Guideline (revised) 8.9.2.
- Broad, A.J., Sutherland, S.K. & Coulter, A.R (1979) The lethality in mice of dangerous Australian and other snake venom. *Toxicon* 17: 661–664.
[https://doi.org/10.1016/0041-0101\(79\)90245-9](https://doi.org/10.1016/0041-0101(79)90245-9)
- Bush, B. and Maryan, B. (2011) *Field Guide to the Snakes of the Pilbara*. West. Aust. Mus., Perth, WA. 1–112.
- Bush, B. (2013) Perseverance prevails: captive reproduction in the Spotted Mulga Snake (*Pseudechis butleri*). *Scales and Tails* 29: 29–32.
- Bush, B. (2016) Snakebite deaths in Western Australia 1980–2016 (December).
<http://members.iinet.net.au/~bush/wadeaths.html>

- Bush, S.P., Green, S.M., Laack, T.A., Hayes, W.K., Cardwell, M.D and Tanen, D.A. (2004) Pressure immobilization delays mortality and increases intracompartmental pressure after artificial intramuscular rattlesnake envenomation in a porcine model. *Ann. Emerg. Med.* **44**: 599–604.
<https://doi.org/10.1016/j.annemergmed.2004.06.007>
PMid:15573035
- Harris, J.B. (1983) Myotoxicity of animal toxins. Proceedings of the 5th European Symposium on animal, plant and microbial toxins, Hannover, 1983, Eds, Mebs, Habermehl.
- Harvey, P.H., Tabrett, D.G., Solomons, B.J. and Thomas, M.A.B. (1982) Envenomation by a King Island Tiger Snake (*Notechis ater humphreysi*). *Med. J. Aust.* **2**: 192–3.
- Isbister, G.K., Halkidis, L., O’Leary, M.A., Whitaker, R., Cullen, P., Mulcahy, R., Bonnin, R. and Brown, S.G. (2010) Human anti-snake venom IgG antibodies in a previously bitten snake-handler, but no protection against local envenoming. *Toxicon* **55** (2–3): 646–649.
<https://doi.org/10.1016/j.toxicon.2009.07.034>
- Isbister, G.K., Brown, S.G., Page, C.B., McCoubrie, D.L., Greene, S.L. and Buckley, N.A. (2013) Snakebite in Australia: a practical approach to diagnosis and treatment. *Med. J. Aust.* **199** (11): 763–768.
<https://doi.org/10.5694/mja12.11172>
- Jelinek, G.A., Tweed, C., Lynch, D., Celenza, T., Bush, B. and Michalopoulos, N. (2004) Cross reactivity between venomous, mildly venomous, and non-venomous snake venoms with the Commonwealth Serum Laboratories Venom Detection Kit. *Emergency Medicine Australasia* **16**: 459–464.
<https://doi.org/10.1111/j.1742-6723.2004.00650.x>
PMid:15537410
- Johnston, C.I., Brown, S.G., O’Leary, M.A., Currie, B.J., Greenberg, R., Taylor, M., White, J. and Isbister, G.K. (2013) Mulga snake (*Pseudechis australis*) envenoming: a spectrum of myotoxicity, anticoagulant coagulopathy, haemolysis and the role of early antivenom therapy – Australian Snakebite Project (ASP-19). *Clin. Toxicol. (Phila)*. **51** (5): 417–424.
<https://doi.org/10.3109/15563650.2013.787535>
PMid:23586640
- Johnston, C.I., Ryan, M.N., Page, C.B., Buckley, N.A., Brown, S.G., O’Leary, M.A. and Isbister, G.K. (2017) The Australian Snakebite Project, 2005–2015 (ASP-20). *Med. J. Aust.* **207** (3): 119–225.
<https://doi.org/10.5694/mja17.00094>
PMid:28764620
- Marshall, L.R. and Herrmann, R.P. (1983) Coagulant and anticoagulant actions of Australian snake venoms. *Thrombosis and Haemostasis Research* (Stuttgart) **50** (3): 707–711.
- Mirtschin, P. (2006) The pioneers of venom production for Australian antivenoms. *Toxicon* **48**: 899–918.
<https://doi.org/10.1016/j.toxicon.2006.07.026>
PMid:16938322
- Razavi, S., Weinstein, S.A, Bates, D.J., Alfred, S. and White, J. (2014) The Australian mulga snake (*Pseudechis australis*: Elapidae): report of a large case series of bites and review of current knowledge. *Toxicon* **85**: 17–26.
<https://doi.org/10.1016/j.toxicon.2014.04.003>
PMid:24726467
- St John Ambulance Service. (2014) Snakebite first aid.
http://stjohn.org.au/assets/uploads/fact%20sheets/english/FS_snakebite.pdf
- Sutherland, S.K., Coulter, A.R. and Harris, R.D. (1979) Rationalisation of first-aid measures for elapid snakebite. *Lancet* **1** (8109): 183–186.
[https://doi.org/10.1016/S0140-6736\(79\)90580-4](https://doi.org/10.1016/S0140-6736(79)90580-4)
- Sutherland, S.K., Coulter, A.R. and Harris, R.D., Lovering, K.E and Roberts, I.D. (1981a) A study of the major Australian snake venoms in the monkey (*Macaca fascicularis*); (1) The movement of injected venom; methods which retard this movement, and the response to antivenoms. *Pathology* **13**: 13–27.
<https://doi.org/10.3109/00313028109086826>
PMid:7220094
- Sutherland, S.K., Campbell, D.G. and Stubbs, A.E. (1981b) A study of the major Australian snake venoms in the monkey (*Macaca fascicularis*); II: myolytic and haematological effects of venoms. *Pathology* **13**: 705–715.
<https://doi.org/10.3109/00313028109086644>
PMid:7335377
- Sutherland S.K. and Tibballs J. (2001) *Australian Animal Toxins: the Creatures, Their Toxins and Care of the Poisoned Patient*. South Melbourne: Oxford University Press.
- Welton, R.E., Williams, D.J and Liew, D. (2017) Injury trends from envenoming in Australia, 2000–2013. *Toxicon* **47** (2): 170–176.
<https://doi.org/10.1111/imj.13297>

Health Promotion Services. (1997) Snakebite First Aid. Health Department of Western Australia, East Perth. HP 2153.

White, J. (1987) Elapid snakes: aspects of envenomation. In *Toxic Plants & Animals: A Guide For Australia*. Eds. Jeanette Covacevich, Peter Davie and John Pearn. Qld Museum, Brisbane.

White, J. (1995) *CSL Antivenom Handbook*. CSL Ltd., Parkville, Vic. 1–63.

White, J. (1998) Envenoming and antivenom use in Australia. *Toxicon* **36** (11): 1483–1492.
[https://doi.org/10.1016/S0041-0101\(98\)00138-X](https://doi.org/10.1016/S0041-0101(98)00138-X)

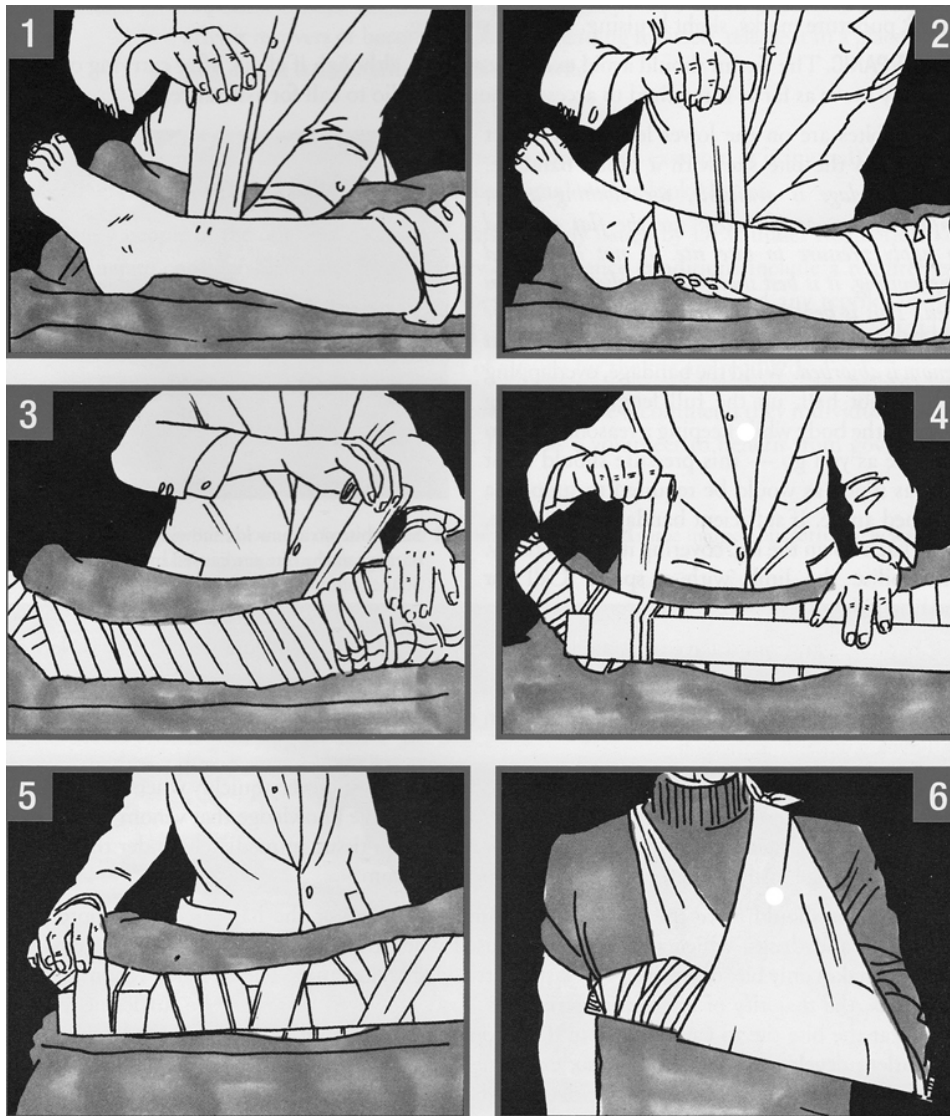


FIGURE 1. Sutherland *et al.*'s original 1979 Australian snakebite first aid reproduced from Bush and Maryan (2011). This is the most straightforward and appropriate first aid available and any modifications or variations to it will result in confusion and anxiety in snakebite victims.

Date	Hospital	Species	Necrosis
1963	St Georges Kogarah NSW	<i>Pseudechis porphyriacus</i>	No
1988	Wyalkatchem WA	<i>Pseudonaja nuchalis</i>	No
1988	Royal Perth WA	<i>Notechis scutatus</i>	Yes
1994	Royal Perth WA	<i>Pseudonaja nuchalis</i>	No
1997	Sir Charles Gardiner	<i>Pseudechis australis</i>	Yes
2000	Royal Perth WA	<i>Pseudonaja affinis</i>	No
2016	Port Hedland WA	<i>Pseudonaja nuchalis</i>	No

TABLE 1. The author's snakebite history where medical intervention occurred, including hospital, species involved and if bite site necrosis occurred.



FIGURE 2. The large (160cm) female Common Mulga Snake (*Pseudechis australis*) responsible for the bite that caused decomposition of author's left index finger.

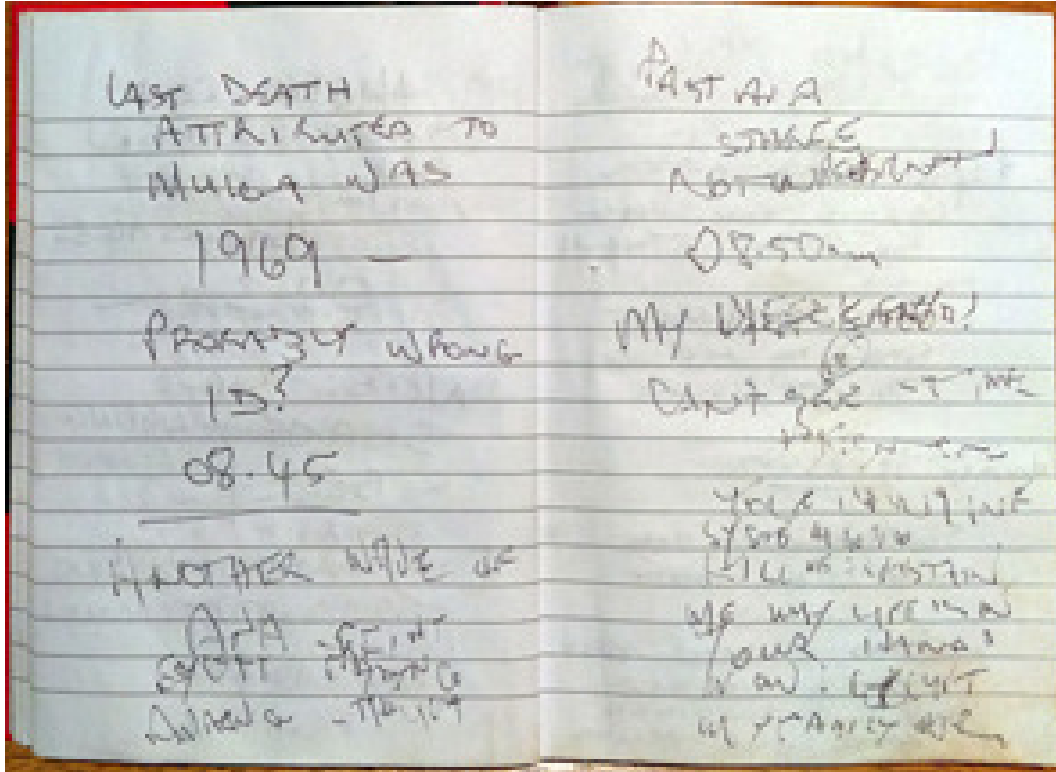


FIGURE 3. The author's notes progressively becoming indecipherable ninety minutes after bite from Common Mulga Snake (*Pseudechis australis*).

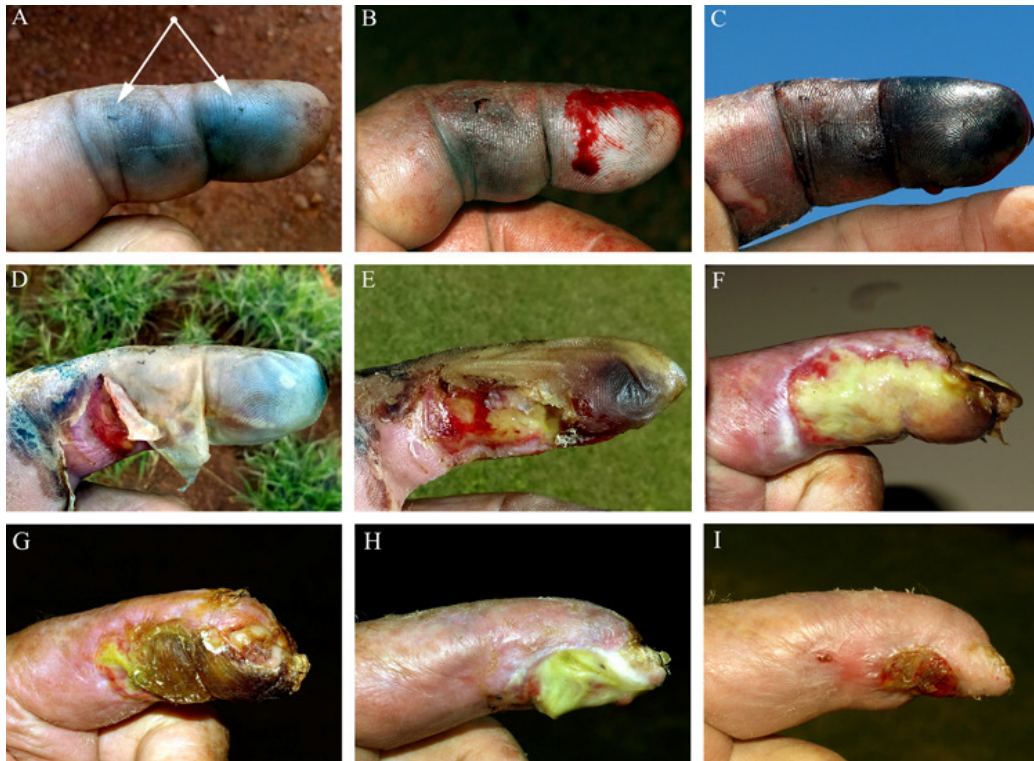

FIGURE 4. Progressive destruction and partial recovery of author's index finger, left hand after bite from Common Mulga Snake (*Pseudechis australis*) reported here. The post bite time of each photo is A – 7 hours, B – 24 hours, C – 6 days, D – 19 days, E – 21 days, F – 28 days, G – 46 days, H – 95 days and I – 113 days.

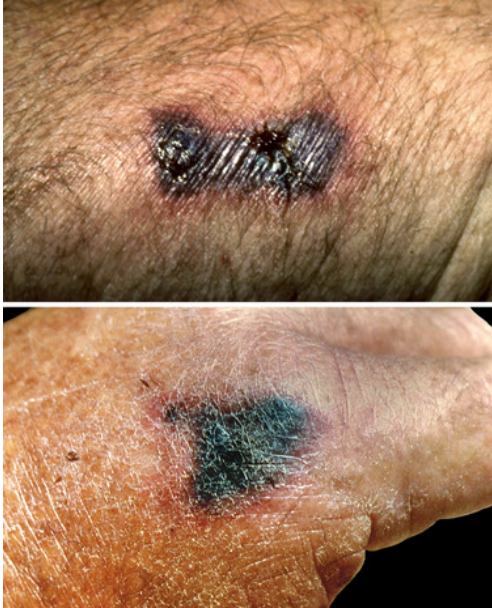

FIGURE 5. Localised necrosis experienced by the author following previous envenomations by Tiger Snake (*Notechis scutatus*) on outside of right wrist at twenty-four hours post bite (top) and Common Mulga Snake (*Pseudechis australis*) on index knuckle of left hand at forty-eight hours post bite (bottom). In both cases, pressure was applied directly over bite site immediately post bite resulting in permanent scarring.